# RHINOPLASTY

## AESTHETIC-PLASTIC SURGERY OF THE NOSE

**Prof. Alexander BERGHAUS, M.D.**

**University Professor and Acting Chairman,**
**ENT Clinic and Polyclinic of the**
**Grosshadern University Hospital, Munich, Germany**

The **anatomical-surgical illustrations** were made by**:**
**Katja Dalkowski,** M.D.,
Grasweg 42, D-91054 Buckenhof, Germany

**Please note:**
Medical knowledge is ever changing. As new research and clinical experience broaden our knowledge, changes in treatment and therapy may be required. The authors and editors of the material herein have consulted sources believed to be reliable in their efforts to provide information that is complete and in accordance with the standards accepted at the time of publication. However, in view of the possibility of human error by the authors, editors, or publisher of the work herein, or changes in medical knowledge, neither the authors, editors, publisher, nor any other party who has been involved in the preparation of this work, warrants that the information contained herein is in every respect accurate or complete, and they are not responsible for any errors or omissions or for the results obtained from use of such information. The information contained herein is intended for use by doctors and other health care professionals. It is not intended for use as a basis for treatment decisions, and is not a substitute for professional consultation and/or use of peer-reviewed medical literature. Readers are encouraged to confirm the information contained herein with other sources.

Some of the product names, patents, and registered designs referred to in this book are in fact registered trademarks or proprietary names even though specific reference to this fact is not always made in the text. Therefore, the appearance of a name without designation as proprietary is not to be construed as a representation by the publisher that it is in the public domain.

**Rhinoplasty – Aesthetic Plastic Surgery of the Nose**

Prof. **Alexander Berghaus,** M.D.
University Professor and Acting Chairman of the ENT Clinic and Polyclinic of the Grosshadern University Hospital, affiliated with the Ludwig Maximilian University Munich, Germany

**Contact:**
Prof. **Alexander Berghaus,** M.D.
Direktor der Klinik und Poliklinik für Hals-Nasen-Ohrenheilkunde
der Ludwig-Maximilians-Universität München,
Klinikum Grosshadern
Marchioninistraße 15
D-81366 München, Germany
Phone: +49 (0)89 / 70 95 29 90
Fax: +49 (0)89 / 70 95 88 91
E-mail: Alexander.Berghaus@med.uni-muenchen.de


ISBN 978-3-89756-553-1, Printed in Germany
P.O. Box, D-78503 Tuttlingen
Phone: +49 74 61 / 14 590
Fax: +49 74 61 / 708-529
E-mail: Endopress@t-online.de

Editions in languages other than English and German are in preparation. For up-to-date information, please contact Endo Press®, Tuttlingen, Germany, at the address shown above.

**Typesetting and Lithography:**
Andy Ziegler Typographie, D-78054 VS-Schwenningen, Germany
Eller repro+druck, D-78056 VS-Schwenningen, Germany

**Printed by:**
Straub Druck+Medien AG
D-78713 Schramberg, Germany

11.14-0.5

# Table of Contents

**Fig. 1**
The statue of Doryphoros.

# 1.0 Rhinoplasty – Reasons and Justification

Mankind's search for a measure of beauty in himself and his surroundings is hardly a new phenomenon. Efforts by the ancient Greeks to erect statues of optimal proportions are legendary evidence of this desire. In the 5th Century BC, Polycletes said: "All physicians and philosophers see the beauty of the human body in the symmetrical proportions of the limbs". The statue of Doryphoros is based on the proportionality canon of Polycletes (**Fig. 1**). Complicated in its details, this canon aims at balancing the represented shape by mathematical calculation of all lengths and distances on the basis of the smallest units (**Figs. 2a+b**).

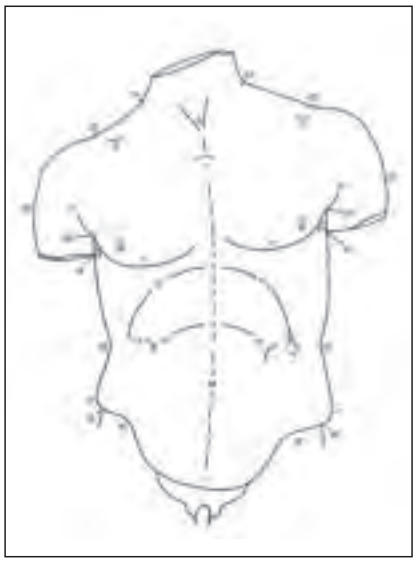

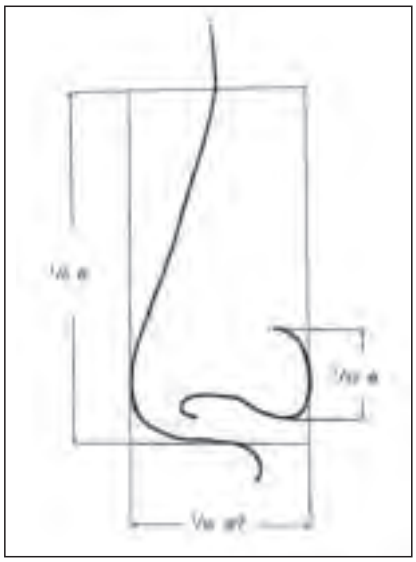

**Figs. 2a+b**
The dimensions of the torso and nose of Doryphoros conform to the proportionality canon of Polycletes (5th century BC; according to Steuben).

The fundamental understanding behind this artistic interpretation was to consider beauty not as a randomly occurring feature but rather as an exact adherence to certain quantifiable criteria.

The same considerations inspired Leonardo da Vinci and Albrecht Dürer in the 15th and 16th centuries, especially the proportionality system of Vitruvius (**Figs. 3+4**). Similar systems for the calculation of beauty in artistic representations can be found in most cultures, for example since the 6th century in India.

With the development of the teachings of physiognomy as early as the 16th century, a lack of beauty began to be considered not only a failure to comply with some external standards, but also a sign of possible criminal tendencies or mental defect. These theories were put forward mainly by Della Porta, Lavater, and Lombroso (**Figs. 5a+b**).

**Fig. 3**
Measurement of facial dimensions according to Leonardo da Vinci (15th century).

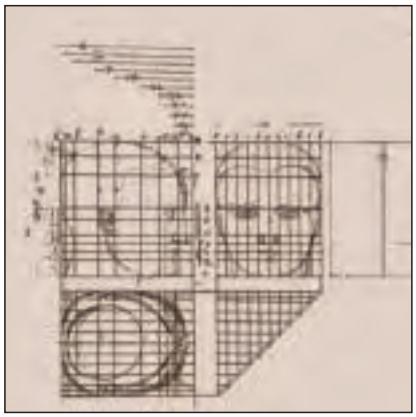

**Fig. 4**
Proportionality of the head according to Albrecht Dürer (16th century).

**Fig. 5a+5b**
Comparison of human and animal facial features in the teachings of physiognomy of Della Porta (16th century).

**Fig. 6**
Prof. Jacques Joseph, M.D. (1865–1933). Pioneer of aesthetic-plastic surgery of the nose.

Keeping this understanding in mind, it comes as no surprise that the wish to alter one's external appearance gained in significance where physical features failed to comply with certain standards of ideal beauty. These tendencies were only increased by man's long-standing yearning for eternal youth, for instance as reflected by external features of the young nose compared with old age (**Fig. 7,** refer to **Fig. 8b**).

Aside from functional disorders that call for rhinoplasty with the aim of improving nasal airway patency, the motivation of individuals seeking rhinoplasty seems largely based on man's desire to appear more attractive, younger, or just different.

However, surgical techniques for re-shaping the nose were developed only relatively recently. One of the great pioneers of aesthetic plastic surgery of the nose was Jacob Joseph, born in Königsberg (Kaliningrad) in 1865 (**Fig. 6**). He became the most renowned plastic facial surgeon of his time and founded a surgical school of international repute. Without detracting from the achievements of his contemporaries and successors, Joseph may be called the founder of modern aesthetic rhinoplasty. Many of the acknowledged technical details of rhinoplastic procedures can be traced back to Joseph, and even today the aesthetic rhinosurgeon utilizes some instruments designed by Joseph. When introducing improvements to old methods, we pay respect and acknowledge Joseph and our other predecessors and teachers.

**Fig. 7**
Lucas Cranach, the Elder: "Der Jungbrunnen", 1546, Art Gallery of the State Museum Berlin, Germany. (Gemäldegalerie Staatliche Museen, Berlin).

# 2.0 Anatomy of the Nose and Facial Proportions

The sturdy nasal framework comprises the nasal bones and the bony cartilaginous septum with the triangular cartilages (upper lateral cartilages). In contrast, the mobile framework consists of the alar cartilages with medial and lateral crura (lower lateral cartilages). In addition, the nasal turbinates and the individually varying thickness of the skin covering the nose possess functional and aesthetic significance (**Figs. 7a–c**). Sound knowledge of the anatomy of the external and internal nose are a prerequisite for any rhinosurgery.

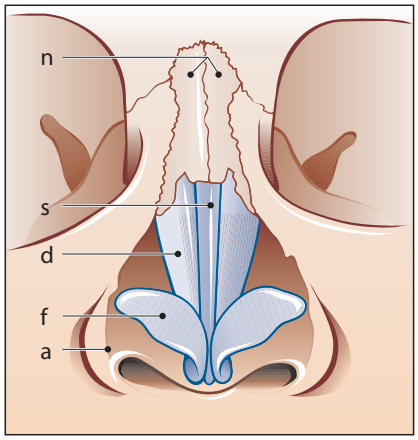


**Fig. 7a**
Anatomy of the nasal framework in frontal view.

**n** – Nasal bone
**s** – Upper edge of the nasal septum
**d** – Triangular cartilage
**f** – Alar cartilage
**a** – Apertura piriformis

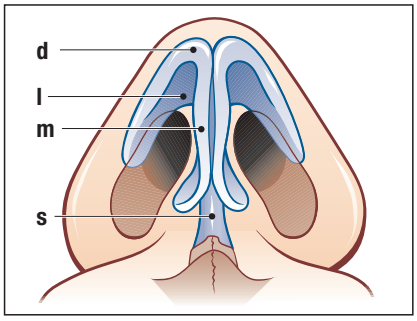


**Fig. 7b**
Caudal view.

**d** – Dome of the alar cartilage
**l** – Lateral crus of the alar cartilage
**m** – Medial crus of the alar cartilage
**s** – Septum

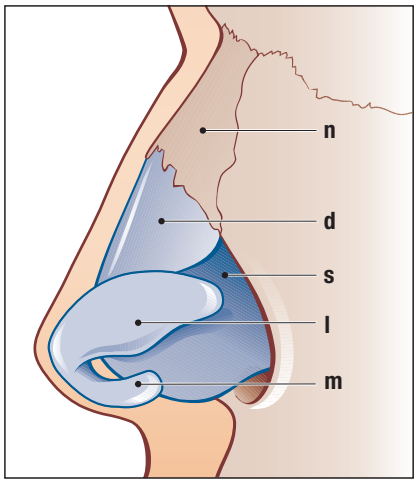


**Fig. 7c**
Lateral view.

**n** – Nasal bone
**d** – Triangular cartilage
**s** – Septum
**l** – Lateral crus of the alar cartilage
**m** – Medial crus of the alar cartilage

## Facial Proportions

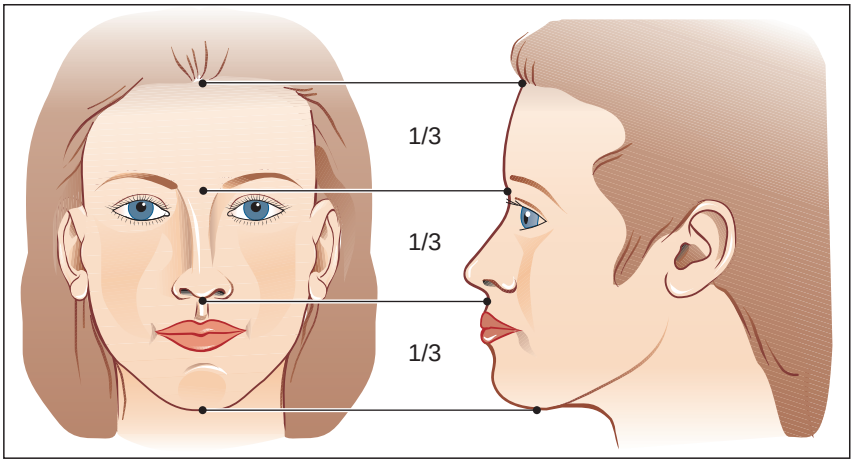


**Fig. 8a**
Upper, middle, and lower third of the face.

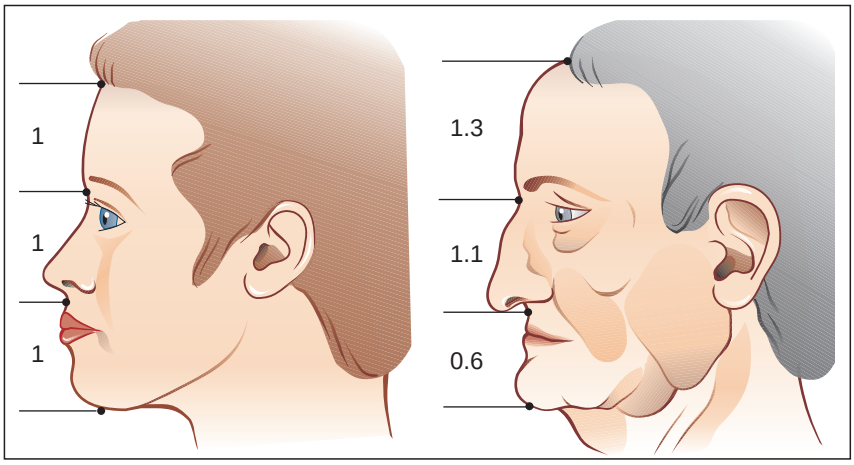


**Fig. 8b**
Change of facial proportions with age favoring the upper portions by receding of the hairline, length increase of the nose, and subsequent loss of teeth and jawbone atrophy.

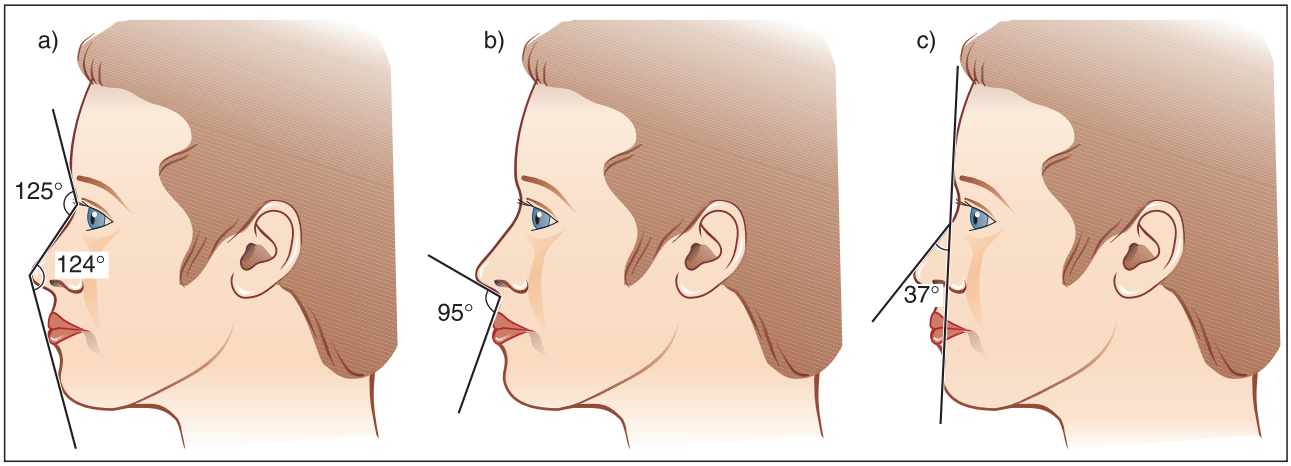


**Fig. 8c**
Significant angles for facial proportionality with normal values:
naso-frontal and naso-mental angles (**a**), naso-labial angle (**b**), naso-facial angle (**c**).

Facial proportions are mainly defined by the nasofacial, nasofrontal, and nasolabial angles, and the length of the nose. Analysis of the facial dimensions is based on recognized topographical landmarks, such as the tip defining point (apex of the nose), glabella (metopion), and points defining the lips and chin (**Figs. 8a–c**). These findings are included in the rhinosurgeon's preoperative assessment and determination of the objectives of surgery. It is evident that the rhinosurgeon should have a well-developed aesthetic feeling for facial proportions.

Obviously, prior to surgery, thorough analysis of the prevailing problem, counseling of the patient as well as a detailed and documented informed consent discussion are the mandatory steps that need to be taken even if the patient leaves all decision-making up to the surgeon.

Moreover, extensively standardized photodocumentation prior to surgery is essential including views from the front, bottom, both sides and the 45°-positions ahead of the subject (¾-view). This ensures sound controls of the post-operative course to be made (**Figs. 29+30,** p. 23/24).

# 3.0 Rhinoplastic Procedures

The following is a description of the surgical steps involved in successful rhinoplasty according to the author's own experience. Other surgeons may prefer to follow a different sequence of surgical steps.

## 3.1 Preoperative Preparation

In the vast majority of cases, rhinoplasty is performed under intubation anesthesia, local anesthesia being the exception. The surface of the nose is washed with a disinfectant. The main nasal cavities are cleaned. Mucosal swelling is reduced by placing cotton swabs soaked in a decongestant. After draping the surgical field, a mixture containing a local anesthetic and adrenaline supplement (xylocaine 2%, suprarenin 1:200,000) is injected under the mucoperichondrium and mucoperiosteum of the septum and the skin of the nasal dorsum. This is usually done with a fine needle (size: 0.6 x 60 mm) using a maximum of 4 ml of injection solution.

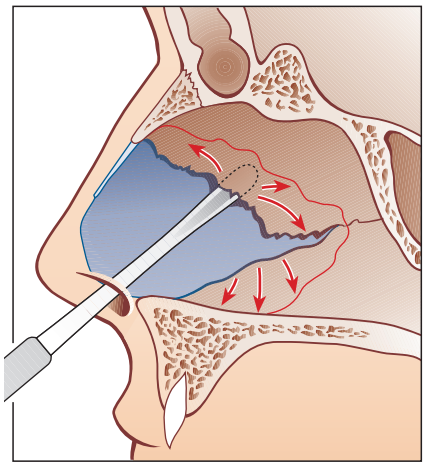

**Fig. 9a**
Septoplasty: subperichondral or subperiosteal elevation of the mucosa and detachment of the bony and cartilaginous septum.

**Fig. 9b**
The very sharp Freer elevator facilitates dissection especially in revision surgery with extensive scarring.

## 3.2 Septoplasty

Primarily for functional reasons, septoplasty is included in many rhinoplasty procedures (septorhinoplasty). Frequently especially with deviated noses the desired aesthetic effect cannot be attained without careful realignment of the nasal septum. Starting in front of the anterior margin of the septum (hemitransfixion incision), the mucoperichondrium is dissected on one side (preferentially the left side). The incision is carried a little ways in the direction of the pyriform aperture allowing the mucosal lining of the nasal floor to be elevated, if required. In cases presenting with pronounced spurs or extreme deviation, the bony and cartilaginous septum and the nasal floor may be exposed bilaterally. Many cases of septal deviation may be treated by strip resection along the lower edge of the quadrangular lamina followed by vertical resection at the junction of the bone of the perpendicular lamina (**Figs. 9a–c**), if required. Depending on the individual case, additional cross-hatching or vertical/horizontal strip incisions of the cartilage may be required. Spur-like deviations of the maxillary crest or the vomer must be removed.

The surgeon must restrain from removing excessive quantities of cartilage to avoid creating deformities in the external appearance. Particularly along the anterior septal margin, cartilage should be reduced only if shortening of the nose and dorsal shift of the columella are desired.

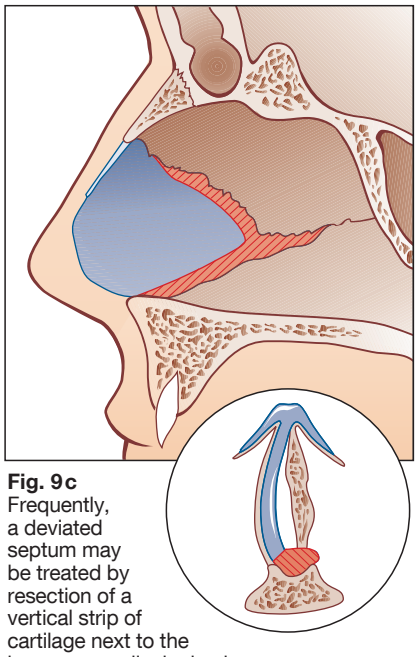

**Fig. 9c**
Frequently, a deviated septum may be treated by resection of a vertical strip of cartilage next to the bony perpendicular lamina and a caudal cartilage batten above the vomer. The domed septum repositions to lie in the midline.

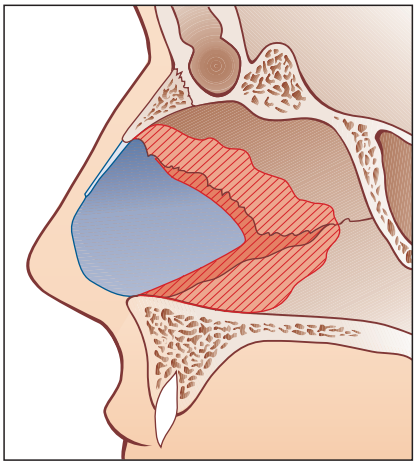

**Fig. 9d**
Deviations in the bony area can be corrected by adequate resection.

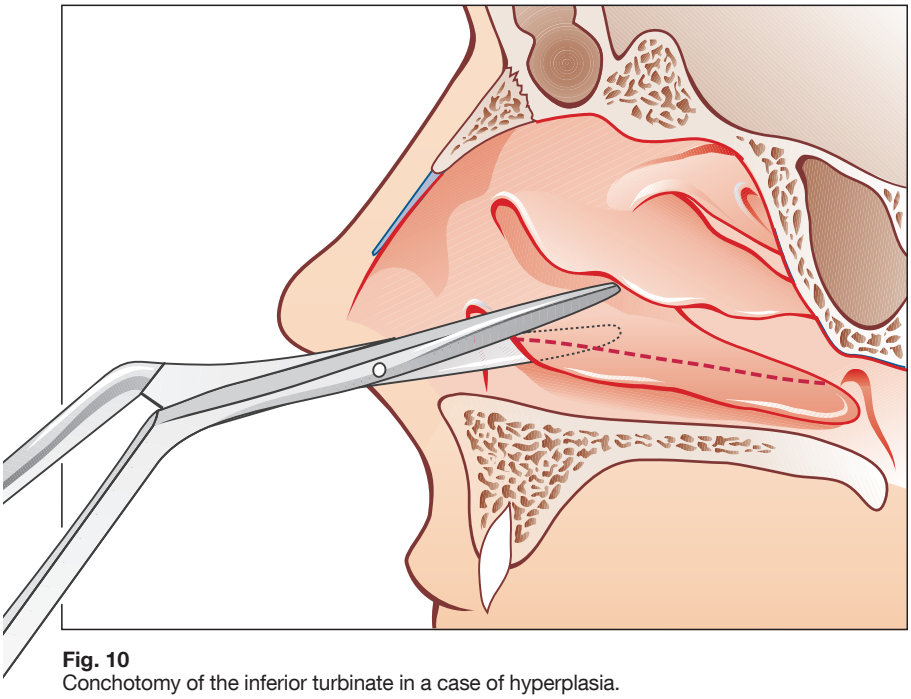

**Fig. 10**
Conchotomy of the inferior turbinate in a case of hyperplasia.

## 3.3 Surgery of the Nasal Turbinates

Hyperplasia of the inferior turbinates frequently contributes significantly to obstruction of the patient's nasal breathing. In this indication, the turbinates are reduced by conchotomy. First, hemorrhage is controlled by electrocoagulation (conchal cautery). Then the soft tissues and (if required) the bony skeleton of the inferior turbinate are reduced with scissors (**Fig. 10**). Any post-conchotomy hemorrhage must be carefully controlled in order to prevent delayed post-operative bleeding (especially from the posterior lateral nasal arteries).

## 3.4 Surgery of the Nasal Tip

Depending on the extent of alar correction required, a transcartilaginous incision may be sufficient for access, whereas in other cases, the need for a more complete view of the alar cartilage may call for using the cartilage delivery technique. However, extensive exposure of the alar cartilage using the delivery approach is associated with an increased risk of inducing asymmetries and increased scar formation. To minimize these risks, the author suggests using an extended inferior approach in pertinent cases. Though less traumatic, this allows complete visualization of the alar cartilages (inferior nasal tip surgery).

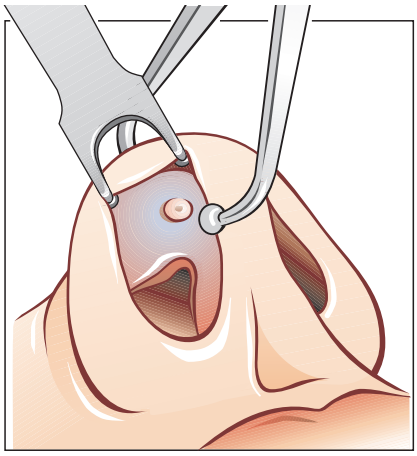

**Fig. 11a**
Marking of the nasal tip point on the inside of the alar cartilage by means of a nasal tip marker.

**Fig. 11b**
Nasal tip marker.

## 3.4.1 Trans-cartilaginous Approach
### (Cartilage Splitting Approach)

**Note:** This method can be used only if the configuration of the caudal margin of the alar cartilage does not need to be corrected.

Whereas the supra-tip region can be narrowed by this method, only very little change to the curvature of the nasal dome is effected. For proper dissection, first identify the tip defining point on each side and the projection on the inside of the nasal vestibule. This is done with a marking instrument which projects the position of the corresponding tip defining point to the inside (**Figs. 11a+b**). The point thus marked corresponds to the medial anterior margin of the incision. Laterally, the incision is carried through the lateral crus along the line of incision of the upper portion of the alar cartilage (**Figs. 12a+b**).

After elevating the skin and exposing the cartilage, the segment of the lateral crus of the alar cartilage to be resected is identified, exposed, and removed (**Figs. 12a+b**).

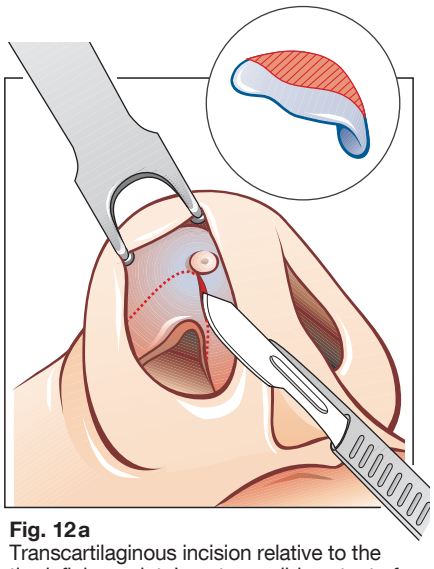

**Fig. 12a**
Transcartilaginous incision relative to the tip defining point. Insert: possible extent of transcartilaginous alar cartilage resection using a transcartilaginous approach.

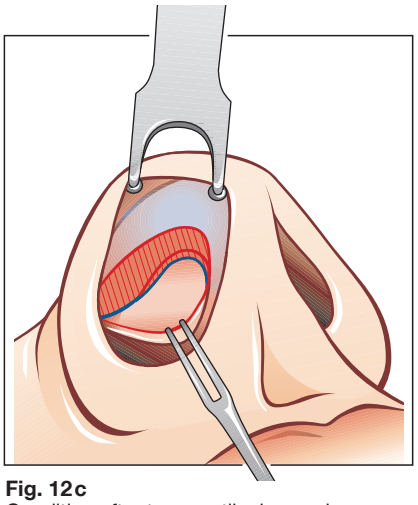

**Fig. 12c**
Condition after transcartilaginous alar cartilage resection showing nasal vestibular skin flap.

**Fig. 12b**
The Kilner hook is equipped with buttons to prevent the instrument from penetrating too deep.

**Fig. 12d**
The strongly angled small ala hook is used to retract skin and cartilage during dissection of the nasal alae.

## 3.4.2 Cartilage Delivery Technique

For complete exposure and clear visualization of the alar cartilages, an intercartilaginous incision is placed at the upper edge of the alar cartilage, in the fold between the anterior marging of the triangular cartilage and the posterior margin of the alar cartilage. The incision is then extended by a second incision along the anterior margin of the alar cartilage (marginal incision) (**Fig. 13a**). The intercartilaginous incision can be combined with a hemitransfixion or transfixion incision at the anterior septal margin. Starting from this marginal incision, the alar skin is undermined as far as the intercartilaginous incision. Now the alar cartilages are completely exposed and delivered into view. Once the appropriate skin layer, that immediately covers the cartilage, has been identified, it is best to expose the alar cartilage by repeatedly opening the scissors (**Figs. 13a+b**). The use of suitable instruments, such as the fork-shaped alar instrument, considerably facilitates delivery of the alar cartilage.

For optimum symmetrical treatment, both cartilages can be placed on the fixed fork-shaped alar instrument with the benefit of side-to-side comparison (**Figs. 13c+d**). Cartilaginous structures should be clearly identified and any soft tissue lining removed prior to this surgical step.

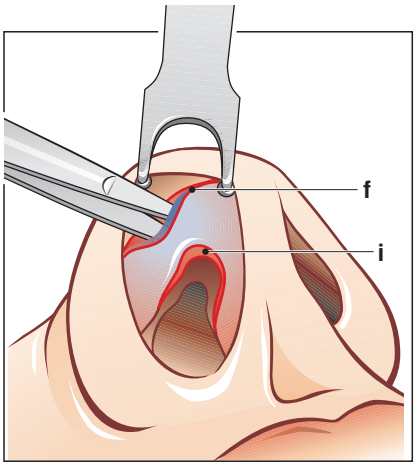


**Fig. 13a**
Lines of incision when using the cartilage delivery technique.
**f** – Incision into the edge of the alar cartilage
**i** – intercartilaginous incision

**Fig. 13b**
The flat, pointed Kilner scissors simplify dissection between skin and cartilage.

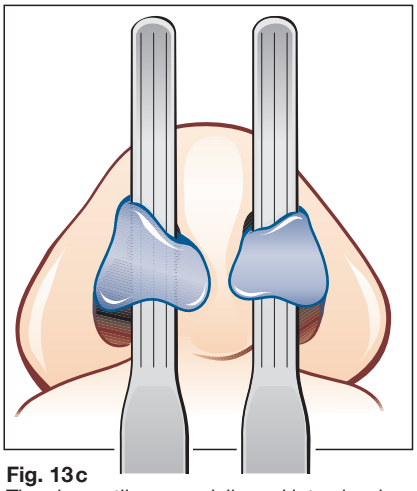

**Fig. 13c**
The alar cartilage are delivered into view by use of the fork-shaped ala instrument.

**Fig. 13d**
The fork-shaped ala instrument can be fixed, which facilitates symmetric dissection of the alar cartilages.

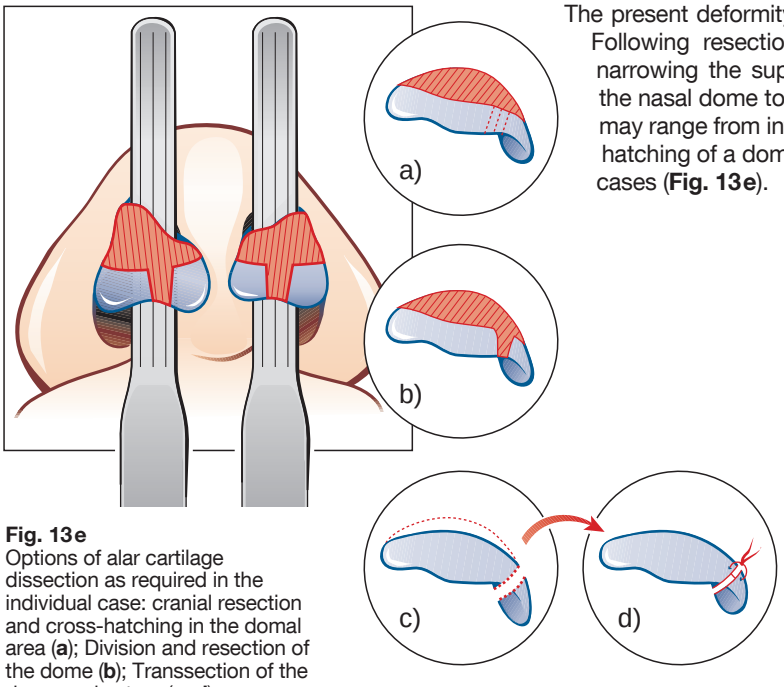


**Fig. 13e**
Options of alar cartilage dissection as required in the individual case: cranial resection and cross-hatching in the domal area (**a**); Division and resection of the dome (**b**); Transsection of the dome and suture (**c, d**).

The present deformity determines the extent of alar cartilage surgery. Following resection of cranial segments of the lateral crura for narrowing the supra-tip region, adjunctive measures are taken at the nasal dome to accentuate the nasal tip profile. These measures may range from interdomal suturing (see **Figs. 15a–c**) or fine cross-hatching of a domal segment to extensive resection in more severe cases (**Fig. 13e**).

In addition, incisions may be made at the junction with the lateral third of the alar cartilage, and the medial crura of the alar cartilage may be reduced in volume. A particularly pronounced narrowing effect of the nasal tip with concurrent prolongation of the columella can be achieved by vertical lobule division and bilateral suturing of the medial crura (Goldman technique, **Figs. 14a+b**). However, in case of a thinned skin the cartilaginous margins of dissection are at risk to “show through” after healing is complete.

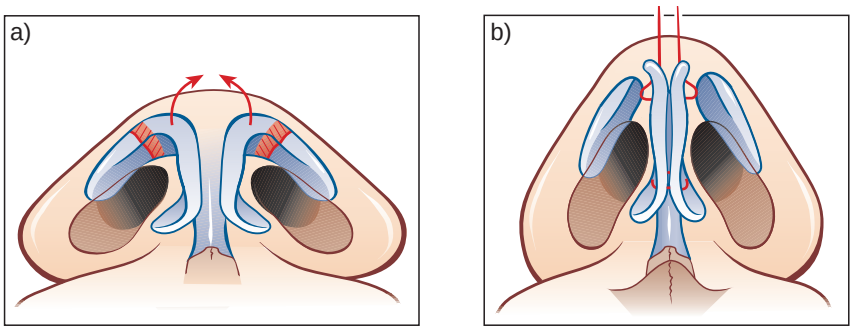


**Figs. 14a+b**
Goldman technique: the alar cartilage is divided lateral to the domal area, and the medial crura are lifted up (**a**). Stabilization by alar cartilage suture (**b**). This technique effectively leads to lengthening of the columella and narrowing of the domal angle.

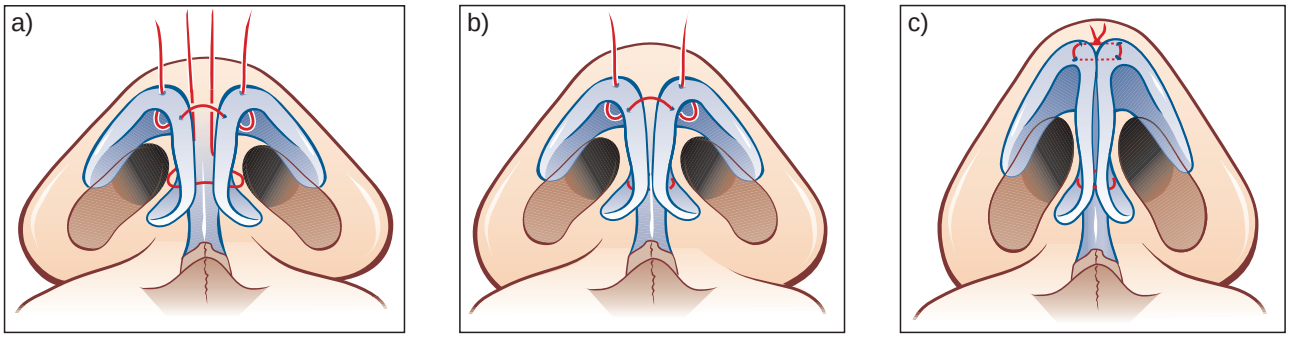


**Figs. 15a–c**
Columellar lengthening by a interdomal suture also provides for an increase in tip projection.

Placement of interdomal sutures may also have a beneficial effect on the configuration of the nasal tip (**Figs.15a–c**).

"Tip grafts" or "shield grafts" are pieces of septal cartilage which are grafted like a shield in front of the alar cartilage at the level of the nasal tip. They are used to improve the nasal tip profile of the tip defining points (**Fig. 16**).

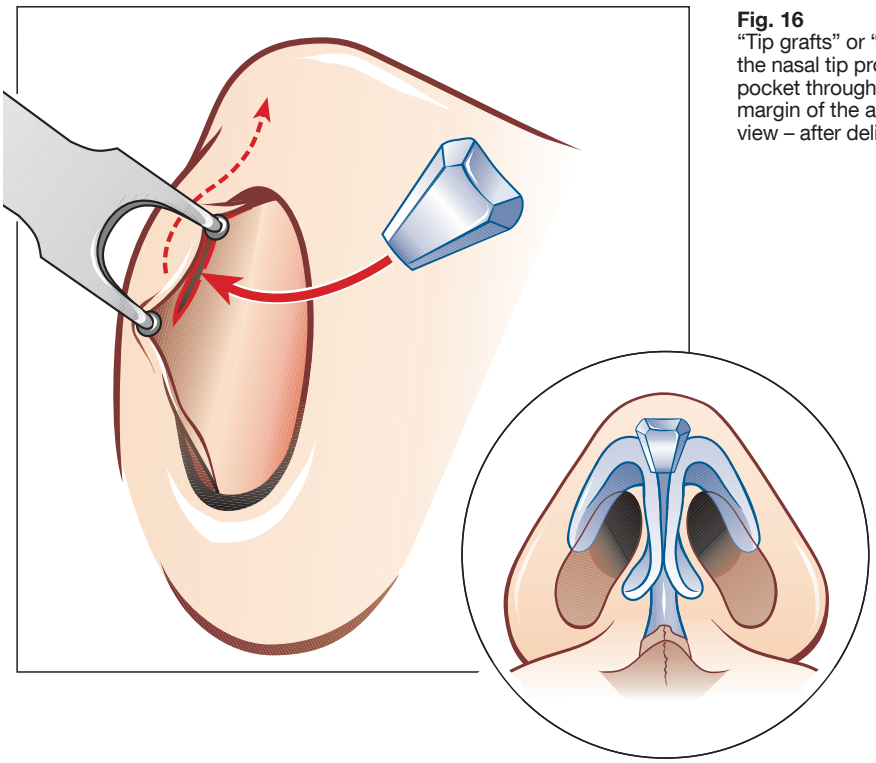

**Fig. 16**
"Tip grafts" or "shield grafts" for improving the nasal tip profile may be placed into a pocket through an incision into the lateral margin of the alar cartilage or – with improved view – after delivery.

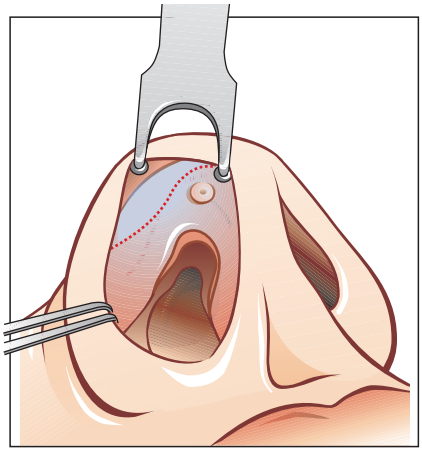

**Fig. 17a**
Inferior nasal tip surgery: in contrast to the transcartilaginous technique (see **Fig. 12**), the incision is made outside the tip defining point and follows the margin of the alar cartilage in medial direction.

### 3.4.3 Extended Inferior Approach
### (“Inferior Nasal Tip Surgery” according to Berghaus)

Even though the cartilage delivery technique offers superior visualization, the necessity of complete exposure of both alar cartilages is occasionally perceived as a disadvantage of this technique. Specifically, the invasiveness of this technique may lead to undesirable asymmetry and to some extent touches on structures which do not require rhinoplastic correction (e.g. large portions of the caudal margin of the alar cartilage).

To preempt these disadvantages, the entire alar cartilage can be caudally dissected in situ. For this purpose, a combination of a transcartilaginous incision and an incision into the margin of the alar cartilage is used. As before, the nasal tip defining points can be marked on the inside with a marking instrument to improve the surgeon’s orientation.

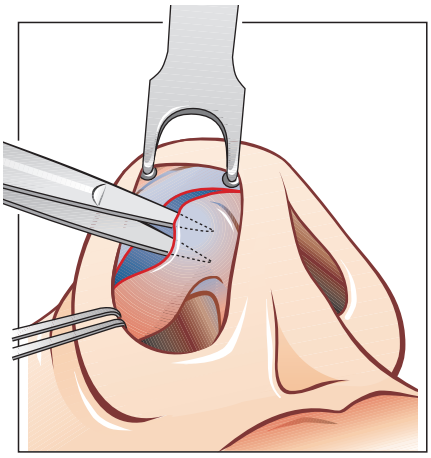

**Fig. 17b**
Dissection of the nasal vestibular flap with flat, pointed Kilner scissors.

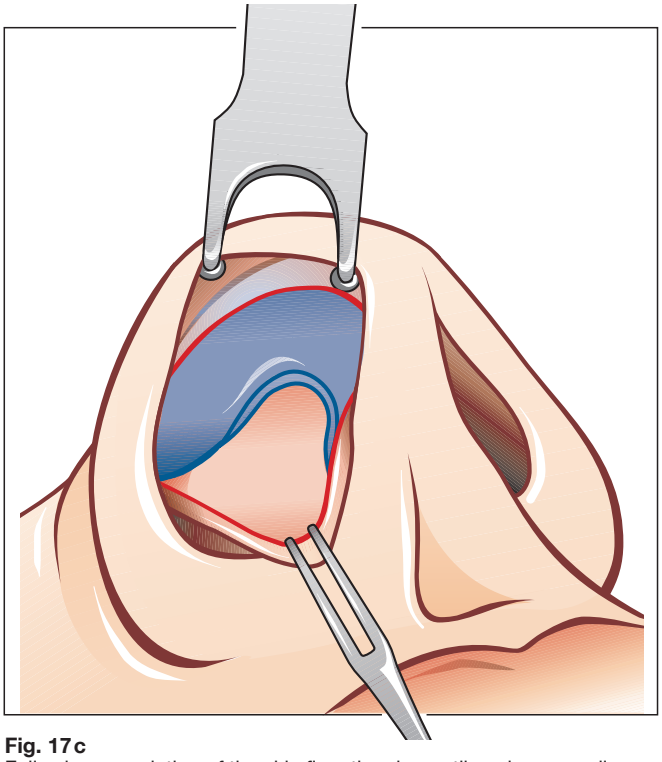

**Fig. 17c**
Following completion of the skin flap, the alar cartilage is very well visualized from a caudal direction.

The lateral alar cartilage is approached with a transcartilaginous incision without disturbing the anterior angle of the alar cartilage, finally joining the marginal incision at the level of the dome (**Figs. 17 a–e**).

Following the line of incision, the surgeon proceeds caudally, dissecting the skin above the alar cartilage in the areas to be treated. The external skin of the nasal tip is not elevated, an intercartilaginous incision is not required. In the next step, the shape of the nasal tip is refined by resection of cranial alar cartilage segments, dome division or resection, and other techniques. The skin flap created by this incision and ensuing dissection of the vestibular skin (hinged on the intercartilaginous fold) is re-approximated at a later time. It can be slightly shortened as required by the extent of alar cartilage surgery.

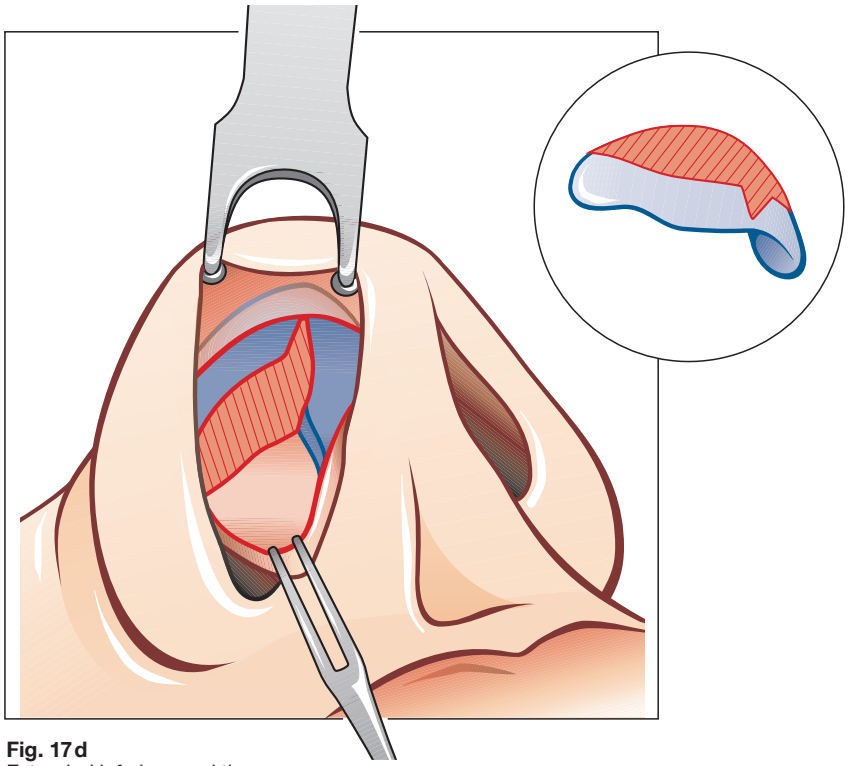

**Fig. 17 d**
Extended inferior nasal tip surgery facilitates correction even in the area of the dome without requiring the cartilage delivery technique.

**Fig. 17 e**
Intra-operative visualization of the situs.

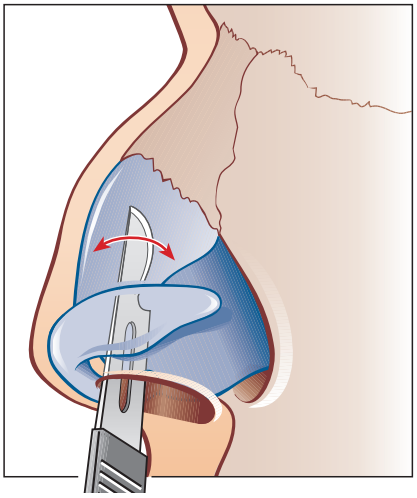

**Fig. 18**
Exposure of the nasal dorsum with a scalpel starting at the intercartilaginous incision.

## 3.5 Surgery of the Nasal Dorsum

Immediately after the intercartilaginous incision is made, the periosteum over the bony pyramid is lifted from its stable bony attachment. Alternatively, this may commence after nasal tip surgery is completed. A no. 15 size scalpel is used in the same subcutaneous plane previously subjected to infiltration anesthesia; the skin is elevated from the sturdy nasal skeleton (**Fig. 18**), but only to the extent required for nasal hump treatment or subsequent osteotomies. Elevation must not be extended too far laterally. During elevation the blade is gently guided along the nasal dorsum without causing damage to the external skin. Small dissection forceps may aid in this step. Completeness of the skin elevation above the upper septal margin in caudal direction must be ascertained. The skin of the nasal dorsum is elevated with a flat, blunt hook.

Prior to proceeding with surgical treatment of the nasal framework, soft tissues located on the upper margin of the septum, especially in the supra-tip region, are removed (**Figs. 19a+b**). Doing so improves visualization of the septal triangular cartilage complex and prevents the formation of a polybeak. This deformity, at least in part, is based on postoperative swelling of soft tissues in the supra-tip region.

Finally, the periosteum above the bony nasal dorsum is lifted with a gentle elevating action (**Figs. 20a+b**).

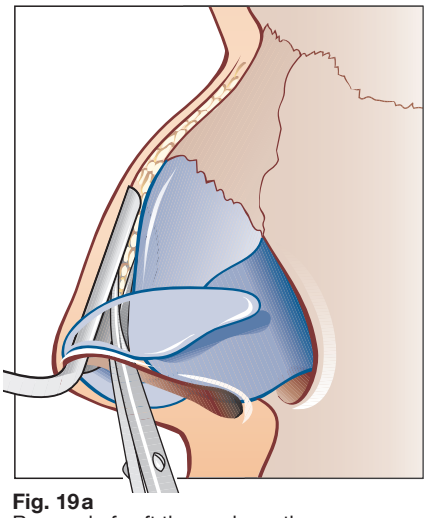

**Fig. 19a**
Removal of soft tissue above the cartilaginous skeleton using scissors.

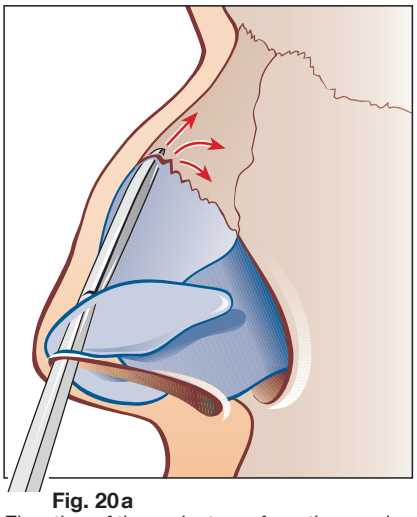

**Fig. 20a**
Elevation of the periosteum from the nasal bone.

**Fig. 19b**
The extended protective lateral portion of the Aufricht retractor improves visibility and protects retracted skin from lesions caused by the scalpel or scissors.

**Fig. 20b**
Modified sharp, slightly curved Joseph elevator for periost preparation.

### 3.5.1 Hump Removal

The stable cartilaginous and bony nasal framework can now be exposed for unobstructed viewing during surgery. Elevate the nasal dorsum skin with an Aufricht retractor or the "winged" modification of this instrument (**Fig. 19b**). The extent of nasal hump removal is determined by a horizontal cartilage incision with a no. 15 scalpel. The incision is extended to the palpable bony margin of the nasal os (**Fig. 21**).

The Rubin instrument with rounded shoulders is inserted into the above defined dissection plane and the incision extended by carefully controlled strokes with a hammer to penetrate the bone until the hump is reduced to the desired degree (**Fig. 22**). The assistant operates the hammer only on the surgeon's order, performing two strokes with the instrument at each incident. This allows for controlled correction and interruption or cessation of this procedure whenever required. Once removed the hump is withdrawn with Blakesley forceps. With the surgeon wearing wet gloves, the nasal dorsum is palpated to detect obvious irregularities or asymmetries at the dissected margins of the nasal bones. Any irregularities detected must be removed at this time with a rasp since this instrument cannot be used on the skeletal bone after mobilization (**Fig. 23a**). By palpation and direct inspection of the cartilaginous nasal dorsum, the surgeon checks if any correction or additional reduction at the dissected margins of the cartilaginous structures are required. Of particular importance are the height/level of the upper margin of the triangular cartilages, which are usually dissected and must be evaluated. This important fine work is performed with a scalpel or robust, yet easy-to-guide, double-jointed, angled nasal scissors (**Figs. 23b+c**).

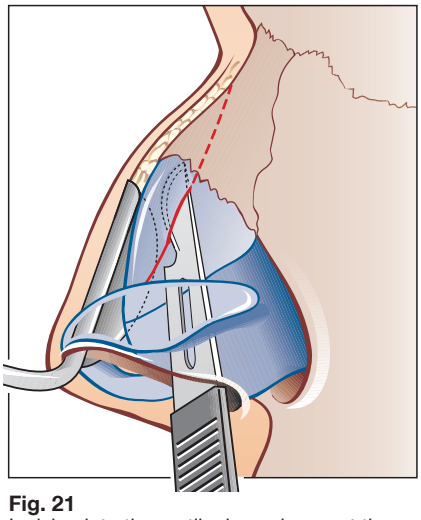

**Fig. 21**
Incision into the cartilaginous hump at the level planned to be used for removal. The protective portion of the Aufricht retractor can be used for abutment.

**Fig. 23c**
Double-jointed, fine, serrated Becker-Caplan scissors are sturdy, but fine enough to permit the most minute cartilage corrections.

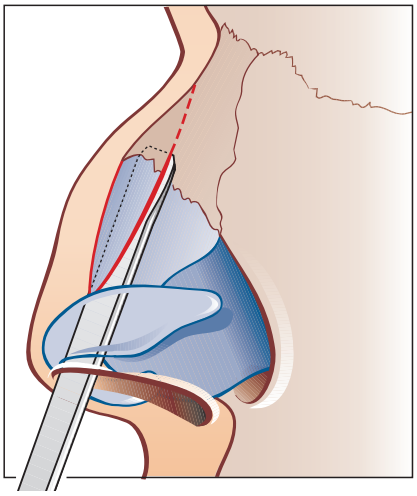

**Fig. 22**
Incision into the cartilage followed by removal of the bony hump with the Rubin osteotome with rounded shoulders.

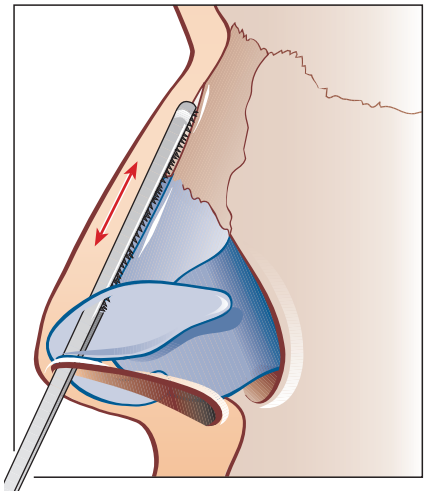

**Fig. 23a**
Finishing of the bony edges with the rasp following hump reduction.

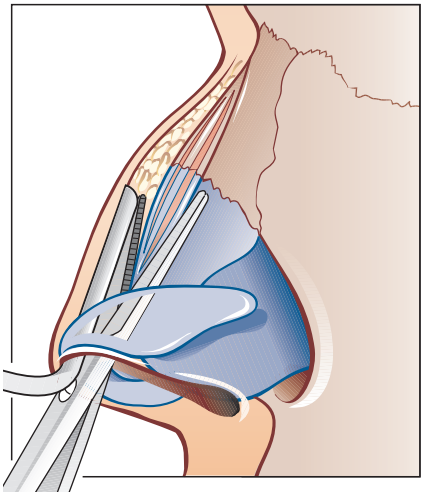

**Fig. 23b**
Finishing of the dissected margins of the cartilage with the double-jointed scissors following hump removal.

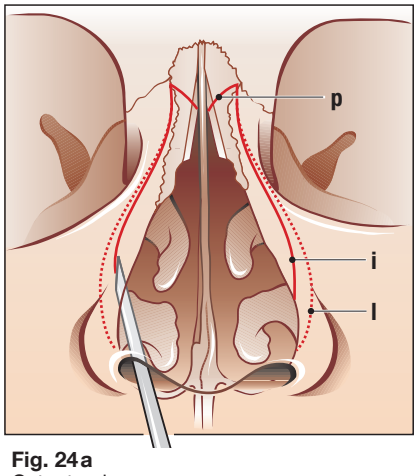


**Fig. 24a**
Osteotomies.
**p** – paramedian osteotomy
**i** – intermediary osteotomy
**l** – lateral osteotomy

**Fig. 24b**
The button on the osteotome indicates the sharp side and facilitates guidance of the instrument.

## 3.5.2 Osteotomy

After hump removal, osteotomies are performed to close and narrow the nasal dorsum. They can also correct a deviated or squat nose. The paramedian osteotomies are performed first. The line of osteotomy runs from the paramedian insertion into the nasal bone and the septum to the middle of the nasal slope just above the medial canthus. A chisel with beveled edges is used (width 2–4 mm, usually 3 mm). Using his finger, the surgeon palpates the position of the tip of the chisel through the skin. The tip of the beveled chisel should constantly point towards latero-cranial which can be easily controlled by a button attached to the instrument handle (**Figs. 24a+b**). Complete mobilization of the lateral framework of the bony nasal skeleton, which will be shifted medially for narrowing, can be achieved only after additional lateral osteotomies. The same chisel is guided in a slightly convex curve from the outer rim of the pyriform aperture in the vestibule to the endpoint of the paramedian osteotomy using the insertion of the inferior turbinate as topographic landmark. At this point, the beveled edge of the chisel points in a medio-cranial direction. The skin of the nasal vestibule is then divided with the chisel. As before, the assistant advances the chisel with two strokes of the hammer under the explicit orders of the surgeon. Once the lateral and paramedian osteotomies join, the separated fragments of the nasal skeleton must be freely mobile. Even minimal residual fixation of these fragments can impair the outcome of surgery. Asymmetrical osteotomies may be required for deviated noses. To achieve harmonic sloping of the nose toward the frontal wall of the maxillary sinus, it is often better to use double lateral osteotomies, with the superior osteotomy being called “intermediary” and performed first.

After completion of the osteotomies and corresponding medial mobilization of the lateral nasal walls, the surgeon verifies that the level of the nasal dorsum is as desired, especially in its cartilaginous sections. The level may need to be corrected (see **Fig. 23b**). Any undesirable bone chips remaining at the glabella are removed with well-aimed strokes on the chisel or use of the rasp.

**Note:** To keep the chisel sharp at all times, use a grindstone made of Arkansas stone (231000, see page 32). This grindstone should be kept on stand-by at all times on the instrument table.

## 3.6 Additional Measures

Frequently, rhinoplasty is complete once the osteotomies are completed, except for wound closure and splintage. However, a final check addresses the question of whether or not specific fine-tuning measures are required. Often the profile of the nasal dorsum may become even more appealing by targeted placement of septum cartilage grafts. Compact cartilage fragments carry an inherent risk of dislocation or unattractive contouring of the skin of the nasal dorsum. Hence, the author prefers to use slightly crushed material for this purpose, which can also be applied in a sandwich technique (**Figs. 25a+b**). Conchal cartilage may be used unless septal cartilage is available. However, because of its fragility conchal cartilage is not as easy to crunch, prone to dislodgement when used as a compact graft, and absorbed to a larger extent than septal cartilage. Larger pieces of conchal cartilage should be temporarily secured in the correct position, e.g. by transcutaneous pilot sutures, whereas crushed cartilage or smaller fragments can be fixed in the desired position with fibrin glue.

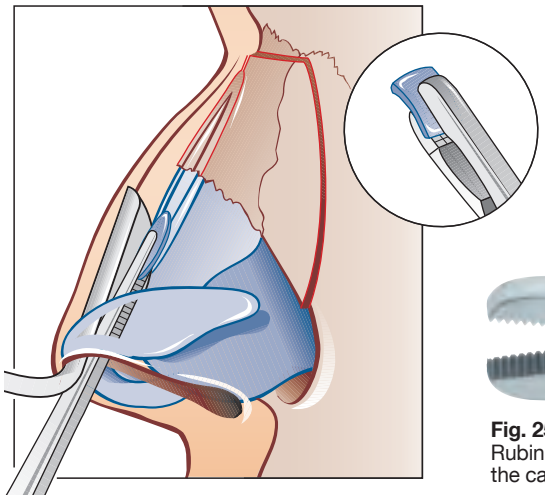

**Fig. 25b**
Rubin septum morzelizer for crushing the cartilage.

**Fig. 25a**
Use of crushed cartilage for profile refinement after hump removal and osteotomies. Insert: bony material is crushed with the Rubin morzelizer. Excessive crushing of the cartilage should be avoided, as it promotes absorption of the cartilage.

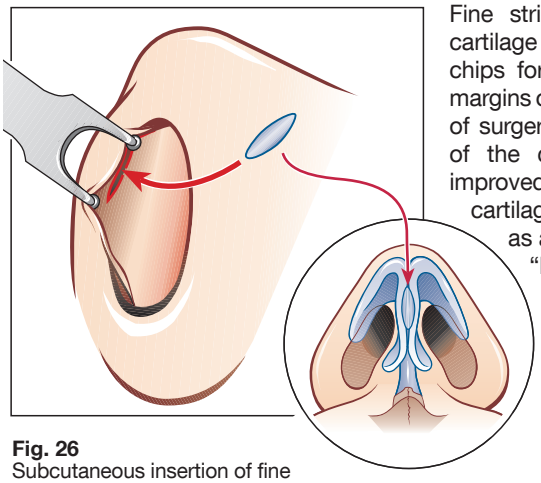

Fine strips or small pieces of septal cartilage are very well-suited for use as chips for contouring the columella and margins of the nasal alae at the conclusion of surgery. In particular, the appearance of the columella can be significantly improved by placing small chips of septal cartilage below this structure to serve as a lining (**Fig. 26**). However, these "buttons" are not to be confused with "tip grafts" or "shield grafts".

**Fig. 26**
Subcutaneous insertion of fine cartilage grafts ("buttons" or "chips") through a lateral collumelar incision intended to improve the columellar profile.

**Fig. 27**
Some examples of nasal splints (models according to Doyle and Reuter).

**Fig. 28**
Aluminum nasal splint. The lateral slits facilitate individualized fitting.

## 3.7 Wound Closure and Dressing

The intranasal incisions are closed with 4 or 5 rapidly absorbable sutures (#0). The septal mucosa is approximated with several rapidly absorbing through-and-through mattress sutures. Occasionally, the septum is fixed bilaterally for a few days using silicone splints fixed anteriorly with a mattress suture (**Fig. 27**). As a preventative measure for postoperative hemorrhage after conchotomy, a finger-shaped tamponade may be placed laterally and inferior.

Externally, the nose is provided with an imbricated (turtle) bandage and an aluminum splint with lateral slits (**Fig. 28**). The tamponade must be secured from sliding out or sliding in (aspiration danger) with prophylactic sutures, which are attached to the nasal splint or skin of the face with adhesive tape. The nasal splint is first changed after 5–6 days.

Subsequently, a new nasal splint is attached and remains in place for 1 week. For control of long-term outcomes, the surgeon conducts regular follow-ups at adequate intervals (ideally for several years) combined with endoscopic care of the inner nose.

## 3.8 Photo Documentation

**Figs. 29/30a–f**
Photo documentation of low-grade hump nose, preoperative (**Fig. 29**) and postoperative (**Fig. 30**) after hump removal and inferior nasal tip refinement (pp. 23+24).

**Preoperative** **and postoperative.**

**Fig. 29a**

**Fig. 30a**

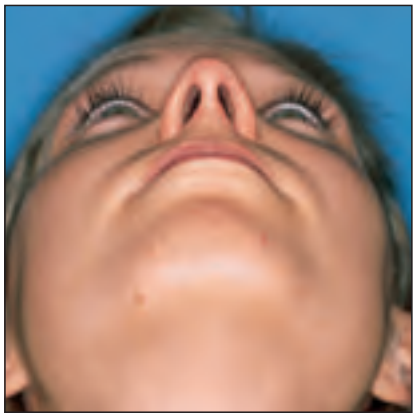

**Fig. 29b**

**Fig. 30b**

**Fig. 29c**

**Fig. 30c**

## Preoperative and postoperative.

Fig. 29 d

Fig. 30 d

Fig. 29 e

Fig. 30 e

Fig. 29 f

Fig. 30 f

**Figs. 29/30a–f**
Photo documentation of low-grade hump nose, preoperative (**Fig. 29**) and postoperative (**Fig. 30**) after hump removal and inferior nasal tip refinement (pp. 23+24).

## 3.8.1 Additional Cases

**Preoperative and postoperative.**

Fig. 31a

Fig. 31b

**Figs. 31a+b**
Hump nose (**a**); after reduction and transcartilaginous nasal tip refinement (**b**).

Fig. 32a

Fig. 32b

**Figs. 32a+b**
Prominent nasal tip deformity (**a**); after refinement (**b**); cartilage delivery technique.

Fig. 33a

Fig. 33b

**Figs. 33a+b**
Mediterranean nasal shape (**a**); after transcartilaginous refinement (**b**).

## Preoperative and postoperative.

Fig. 34a

Fig. 34b

**Figs. 34a+b**
Extensive hump nose (**a**) after removal (**b**) (inferior nasal tip surgery).

Fig. 35a

Fig. 35b

**Figs. 35a+b**
Prominent nasal tip deformity (**a**); after refinement (**b**); (cartilage delivery technique).

Fig. 36a

Fig. 36b

**Figs. 36a+b**
Hump nose (**a**), after removal (**b**); (inferior nasal tip surgery).

## Preoperative and postoperative.

**Figs. 37a-d**
Low-grade saddle nose (**a, c**), after augmentation (**b, d**).

**Fig. 37a**



**Fig. 37b**

**Fig. 37c**

**Fig. 37d**

**Figs. 38a+b**
Prominent saddle nose, before (**a**) and after augmentation (**b**); (costal cartilage, closed technique).

**Fig. 38a**

**Fig. 38b**

## Preoperative and postoperative.

Fig. 39a

Fig. 39b

**Figs. 39a+b**
Bony and cartilaginous deviated nose (**a**), after realignment (**b**): (dislocation).

# Rhinoplasty – Instrumentation for Aesthetic-Plastic Surgery of the Nose

**Set recommended by** Prof. BERGHAUS

**Units and Accessories for Photo-Video Documentation**

**Extracts from the following catalogs:**

**ENDOSCOPES and INSTRUMENTS for ENT**
**and**
**TELEPRESENCE, IMAGING SYSTEMS, DOCUMENTATION – ILLUMINATION**

## Headlight KS60

**with Cold Light Illumination**


310060 **Headlight KS60,** with double lens system and Y-fiber optic light cable, >175,000 lux, illuminated area adjustable from 20 – 80 mm with 40 cm working distance

including:

**Headlight KS60,** with removable and sterilizable Focus Handle 310065

**Headband,** fully adjustable, with Forehead Cushion 078511, with cross band, including holder for Headlight 310063

**Y-Fiber Optic Light Cable,** with special protective casing for Headlight 310063, length 290 cm

**Clip with Band,** for attaching the fiber optic light cable to OR clothing

## HOPKINS® Telescopes – autoclavable

**diameter 2.7 mm, length 18 cm**

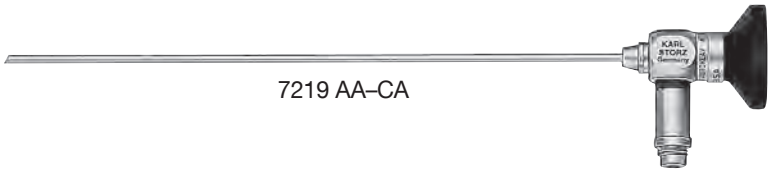


7219 AA–CA

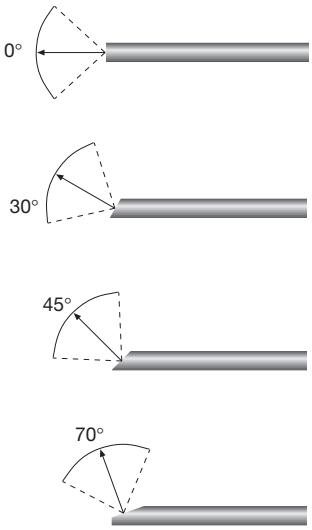


7229 AA **HOPKINS® Straight Forward Telescope 0°,** enlarged view, diameter 2.7 mm, length 18 cm, **autoclavable,** fiber optic light transmission incorporated, color code: green

7229 BA **HOPKINS® Forward-Oblique Telescope 30°,** enlarged view, diameter 2.7 mm, length 18 cm, **autoclavable,** fiber optic light transmission incorporated, color code: red

7229 FA **HOPKINS® Forward-Oblique Telescope 45°,** enlarged view, diameter 2.7 mm, length 18 cm, **autoclavable,** fiber optic light transmission incorporated, color code: black

7229 CA **HOPKINS® Lateral Telescope 70°,** enlarged view, diameter 2.7 mm, length 18 cm, **autoclavable,** fiber optic light transmission incorporated, color code: yellow

**It is recommended to check the suitability of the product for the intended procedure prior to use.**

## HOPKINS® Telescopes – autoclavable

**diameter 4.0 mm, length 18 cm**




7230 AA–CA


7230 AA **HOPKINS® Straight Forward Telescope 0°,**
enlarged view, diameter 4 mm, length 18 cm, **autoclavable,**
fiber optic light transmission incorporated,
color code: green


7230 BA **HOPKINS® Forward-Oblique Telescope 30°,**
enlarged view, diameter 4 mm, length 18 cm, **autoclavable,**
fiber optic light transmission incorporated,
color code: red


7230 FA **HOPKINS® Forward-Oblique Telescope 45°,**
enlarged view, diameter 4 mm, length 18 cm, **autoclavable,**
fiber optic light transmission incorporated,
color code: black

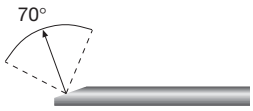


7230 CA **HOPKINS® Lateral Telescope 70°,**
enlarged view, diameter 4 mm, length 18 cm, **autoclavable,**
fiber optic light transmission incorporated,
color code: yellow

## Accessories

**for use with HOPKINS® Telescopes**

723770 STAMMBERGER **Telescope Handle,** flat,
standard model, length 11 cm, for use with HOPKINS®
straight forward telescopes 0° with diameter 4 mm
and length 18 cm

723772 STAMMBERGER **Telescope Handle,** round,
standard model, length 11 cm, for use with HOPKINS®
telescopes 30° – 120° with diameter 4 mm and length 18 cm

723773 STAMMBERGER **Telescope Handle,** round,
length 6.5 cm, for use with HOPKINS® telescopes
with diameter 2.7/3 mm and length 11 cm

723750 B **Protection Tube,** working length 19.7 cm,
for use with HOPKINS® telescopes with length 18 cm

## Rhinoplasty

**Instrumentation for Aesthetic-Plastic Surgery of the Nose**
**Set recommended by** Prof. BERGHAUS
Instrument surfaces specially matted, working ends glossy

488002

488003

488004

488010
488012
488014

488010 – 488014

488018

488022

488023

488024

488022 – 488024


174200

488030


231000

| | |
|---|---|
| 488002 | COTTLE **Nasal Speculum,** extra slender, without set screw, special matt finish, blade length 35 mm, length 13 cm |
| 488003 | **Same,** blade length 55 mm |
| 488004 | **Same,** blade length 75 mm |
| 488010 | RUBIN **Osteotome,** flat, straight, double-edged grinding, rounded corners, with finger grip for controlled osteotome guidance, special matt finish, width 10 mm, length 16.5 cm |
| 488012 | **Same,** width 12 mm |
| 488014 | **Same,** width 14 mm |
| 488018 | KILLIAN-CLAUS **Septum Chisel,** with V-shaped cutting edge, special matt finish, width 5 mm, length 16.5 cm |
| 488022 | **Chisel,** with finger button, flat, special matt finish, width 2 mm, length 18 cm |
| 488023 | **Same,** width 3 mm |
| 488024 | **Same,** width 4 mm |
| 174200 | COTTLE **Metal Mallet,** length 18 cm |
| 231000 | **Hone,** “ARKANSAS” oil stone, wedge-shaped, size 10 x 4 cm |
| 488030 | **Marking Instrument,** for nasal tip, with ball and half cup, straight, special matt finish, length 11 cm |

## Rhinoplasty

**Instrumentation for Aesthetic-Plastic Surgery of the Nose**
**Set recommended by** Prof. BERGHAUS
Instrument surfaces specially matted, working ends glossy


488032


488034


488036


488038


488041


488044


488045
488047


488046


488049
488050

488032 HEYMANN **Nasal Scissors,** medium size, special matt finish, working length 9.5 cm

488034 CRAIG **Septum Forceps,** straight, special matt finish, working length 9 cm

488036 BECKER-CAPLAN **Septum Scissors,** with double joint, serrated, slender, special matt finish, working length 9.5 cm

488038 RUBIN **Septum Morcelizer,** with double joint, straight, special matt finish, length 20 cm

488041 BLAKESLEY **Nasal Forceps,** slender, straight, special matt finish, size 1, working length 11 cm

488044 JANSEN **Nasal Dressing Forceps,** bayonet-shaped, slender, special matt finish, length 16 cm

488045 ADSON-BROWN **Forceps,** micro-model, atraumatic, fine side grasping teeth, special matt finish, length 12 cm

488046 ADSON **Tissue Forceps,** atraumatic, fine side grasping teeth, special matt finish, length 15 cm

488047 ADSON **Tissue Forceps,** 1 x 2 teeth, special matt finish, length 12 cm

488049 KILNER **Scissors,** curved, with tungsten carbide inserts, flat end, sharp/sharp, extra delicate, special matt finish, length 13.5 cm

488050 KILNER **Scissors,** curved, flat end, blunt/blunt, special matt finish, length 15.5 cm

## Rhinoplasty

**Instrumentation for Aesthetic-Plastic Surgery of the Nose**
**Set recommended by** Prof. BERGHAUS
Instrument surfaces specially matted, working ends glossy


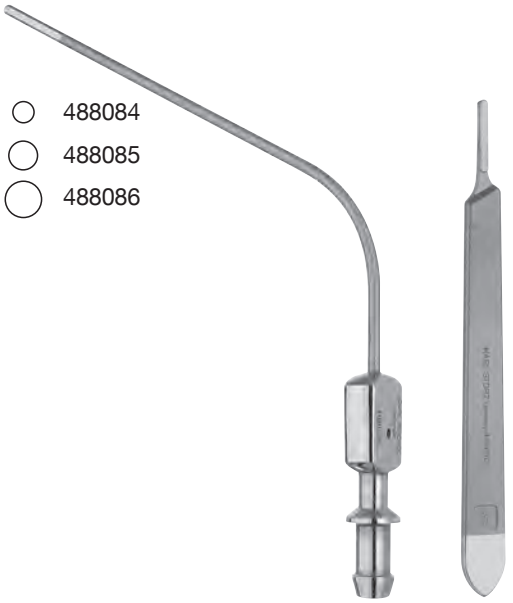


| | |
|---|---|
| 488054 | AUFRICHT **Nasal Retractor,** with side protector, special matt finish, length 16.5 cm |
| 488056 | KILNER **Ala Retractor,** two sharp points with button, special matt finish, width 10 mm, length 8.5 cm |
| 488058 | **Same,** width 13 mm |
| 488060 | **Ala Double Hook,** with octagonal handle, with 2 sharp points, strongly curved, special matt finish, width 2 mm, length 16.5 cm |
| 488065 | BERGHAUS **Ala Guiding Set,** special matt finish, consisting of 2 guiding instruments with distance markings 488065 A and 1 fixation block 488065 B |
| 488070 | JOSEPH **Raspatory,** slightly curved, special matt finish, width 4 mm, length 17.5 cm |
| 488071 | **Same,** strongly curved, width 3.4 mm |
| 488074 | FREER **Elevator,** double-ended, sharp and blunt, special matt finish, length 20 cm |
| 488076 | AUFRICHT **Glabella Rasp,** double-ended, backward cutting, length 20.5 cm |
| 488078 | **Nasal Rasp,** double-ended, coarse, special matt finish, length 21.5 cm |
| 488080 | RYDER **Needle Holder,** tungsten carbide inserts, extra delicate and flat, special matt finish, length 18 cm |
| 488084 | FERGUSON **Suction Tube,** with cut-off hole and stylet, LUER, special matt finish, outer diameter 8 Fr./ 2.5 mm, working length 11 cm |
| 488085 | **Same,** outer diameter 10 Fr./3.5 mm |
| 488086 | **Same,** outer diameter 12 Fr./4.0 mm |
| 488090 | **Scalpel Handle,** No. 3, special matt finish, length 12.5 cm |

## IMAGE1 S Camera System *NEW*

IMAGE1 S

**Economical and future-proof**

- **Modular concept for flexible, rigid and 3D endoscopy as well as new technologies**
- **Forward and backward compatibility with video endoscopes and FULL HD camera heads**
- **Sustainable investment**
- **Compatible with all light sources**


**Innovative Design**

- **Dashboard: Complete overview with intuitive menu guidance**
- **Live menu: User-friendly and customizable**
- **Intelligent icons: Graphic representation changes when settings of connected devices or the entire system are adjusted**
- **Automatic light source control**
- **Side-by-side view: Parallel display of standard image and the Visualization mode**
- **Multiple source control: IMAGE1 S allows the simultaneous display, processing and documentation of image information from two connected image sources, e.g., for hybrid operations**


*Dashboard*

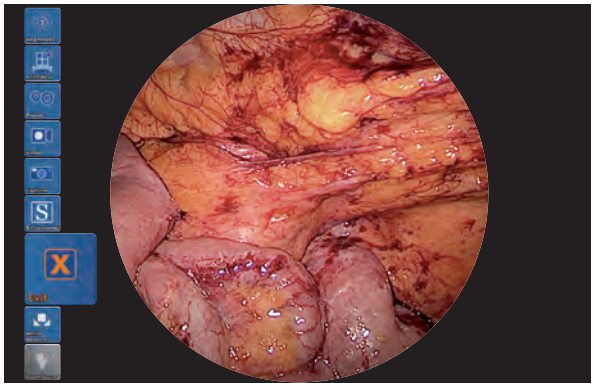


*Live menu*




*Intelligent icons*

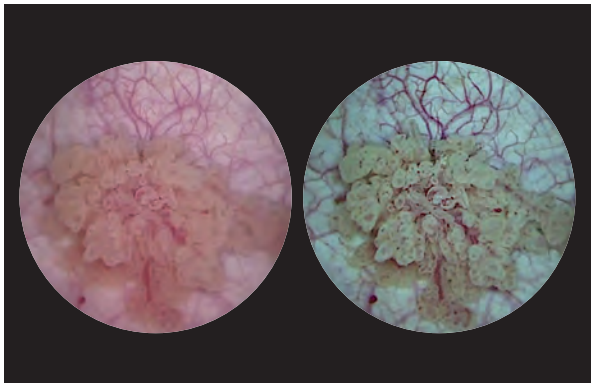

*Side-by-side view: Parallel display of standard image and Visualization mode*

## IMAGE1 S Camera System NEW

IMAGE1 S

**Brillant Imaging**

- **Clear and razor-sharp endoscopic images in FULL HD**
- **Natural color rendition**
- **Reflection is minimized**
- **Multiple IMAGE1 S technologies for homogeneous illumination, contrast enhancement and color shifting**

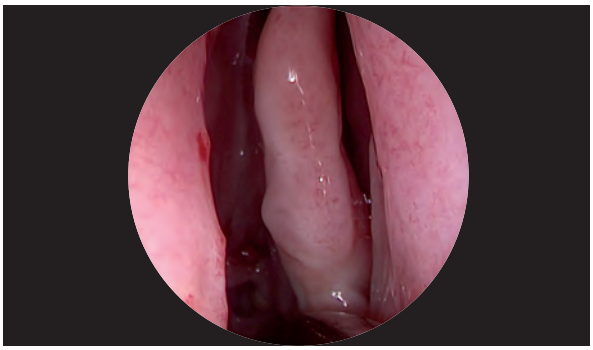

*FULL HD image*

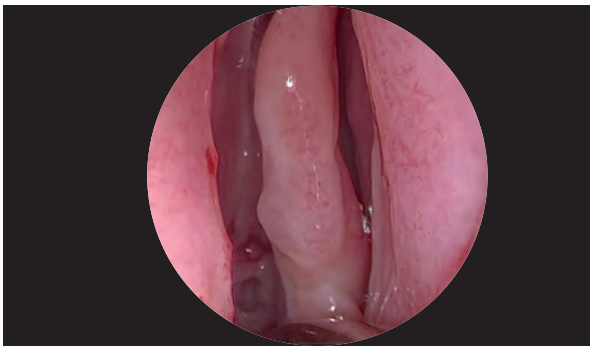

*CLARA*

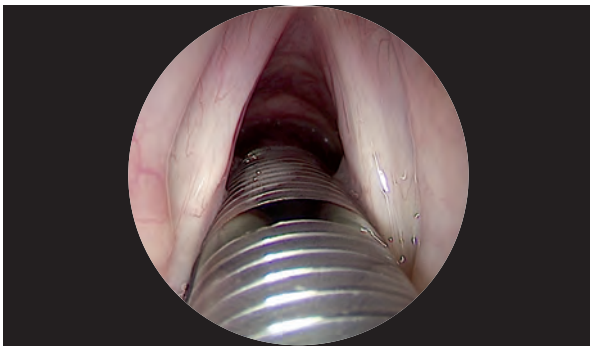

*FULL HD image*

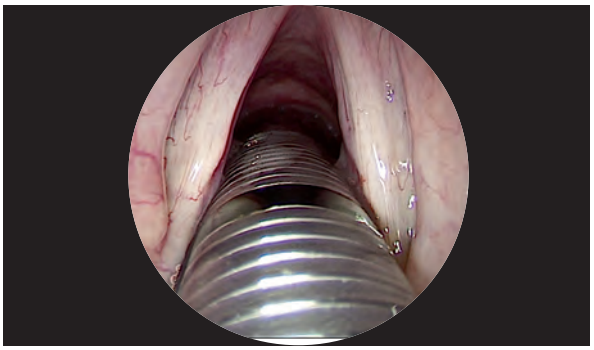

*CHROMA*

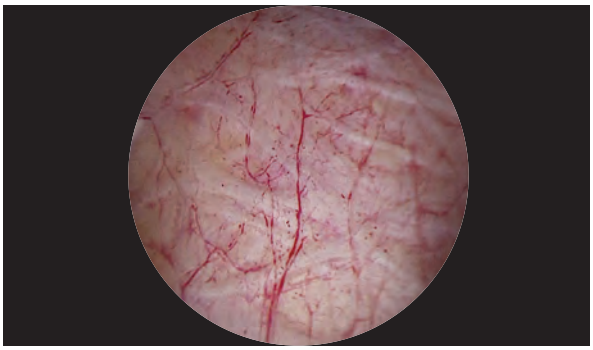

*FULL HD image*

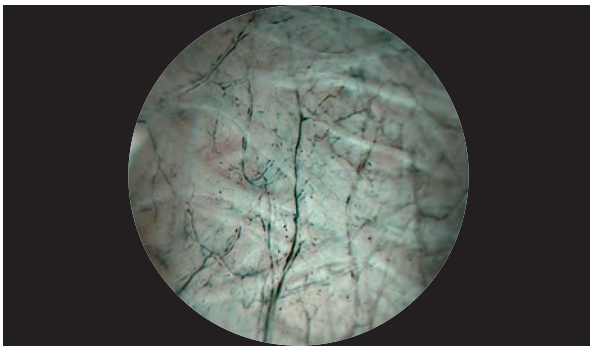

*SPECTRA A**

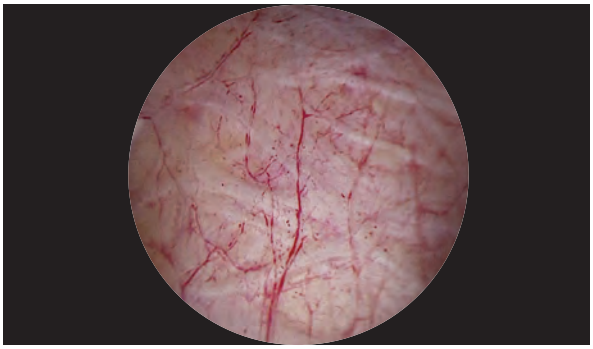

*FULL HD image*

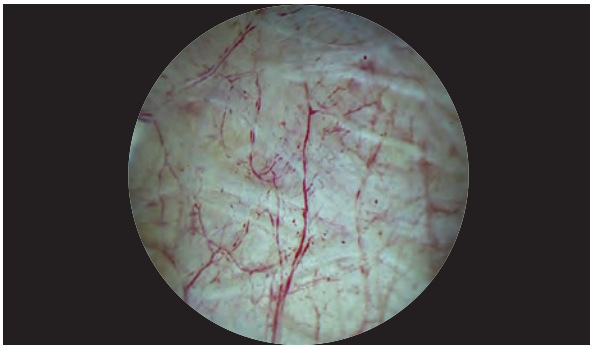

*SPECTRA B***

* *SPECTRA A:* **Not for sale in the U.S.**
** *SPECTRA B:* **Not for sale in the U.S.**

## IMAGE1 S Camera System *NEW*

IMAGE1 S


TC 200EN

TC 200EN* **IMAGE1 S CONNECT**, connect module, for use with up to 3 link modules, resolution 1920 x 1080 pixels, with integrated KARL STORZ-SCB and digital Image Processing Module, power supply 100–120 VAC/200–240 VAC, 50/60 Hz including:
**Mains Cord,** length 300 cm
**DVI-D Connecting Cable,** length 300 cm
**SCB Connecting Cable,** length 100 cm
**USB Flash Drive,** 32 GB, USB silicone keyboard, with touchpad, US
***Available in the following languages:** DE, ES, FR, IT, PT, RU

**Specifications:**

| | |
|---|---|
| HD video outputs | - 2x DVI-D<br>- 1x 3G-SDI |
| Format signal outputs | 1920 x 1080p, 50/60 Hz |
| LINK video inputs | 3x |
| USB interface<br>SCB interface | 4x USB, (2x front, 2x rear)<br>2x 6-pin mini-DIN |

| | |
|---|---|
| Power supply | 100–120 VAC/200–240 VAC |
| Power frequency | 50/60 Hz |
| Protection class | I, CF-Defib |
| Dimensions w x h x d | 305 x 54 x 320 mm |
| Weight | 2.1 kg |

### For use with IMAGE1 S
### IMAGE1 S CONNECT Module TC 200EN

TC 300

TC 300 **IMAGE1 S H3-LINK,** link module, for use with IMAGE1 FULL HD three-chip camera heads, power supply 100–120 VAC/200–240 VAC, 50/60 Hz, **for use with IMAGE1 S CONNECT TC 200EN** including:
**Mains Cord,** length 300 cm
**Link Cable,** length 20 cm

**Specifications:**

| **Camera System** | **TC 300 (H3-Link)** |
|---|---|
| Supported camera heads/video endoscopes | TH 100, TH 101, TH 102, TH 103, TH 104, TH 106<br>(fully compatible with IMAGE1 S)<br>**22**220055-3, **22**220056-3, **22**220053-3, **22**220060-3, **22**220061-3, **22**220054-3, **22**220085-3<br>(compatible without IMAGE1 S technologies CLARA, CHROMA, SPECTRA*) |
| LINK video outputs | 1x |
| Power supply | 100–120 VAC/200–240 VAC |
| Power frequency | 50/60 Hz |
| Protection class | I, CF-Defib |
| Dimensions w x h x d | 305 x 54 x 320 mm |
| Weight | 1.86 kg |

* *SPECTRA A:* **Not for sale in the U.S.**
** *SPECTRA B:* **Not for sale in the U.S.**

## IMAGE1 S Camera Heads *NEW*

IMAGE1 S

**For use with IMAGE1 S Camera System**
**IMAGE1 S CONNECT Module TC 200EN, IMAGE1 S H3-LINK Module TC 300**
**and with all IMAGE1 HUB™ HD Camera Control Units**

TH 100

TH 100 **IMAGE1 S H3-Z Three-Chip FULL HD Camera Head,** 50/60 Hz, IMAGE1 S compatible, progressive scan, soakable, gas- and plasma-sterilizable, with integrated Parfocal Zoom Lens, focal length f = 15–31 mm (2x), 2 freely programmable camera head buttons, for use with IMAGE1 S and IMAGE1 HUB™ HD/HD

**Specifications:**

| IMAGE1 FULL HD Camera Heads | IMAGE1 S H3-Z |
|---|---|
| Product no. | TH 100 |
| Image sensor | 3x ⅓" CCD chip |
| Dimensions w x h x d | 39 x 49 x 114 mm |
| Weight | 270 g |
| Optical interface | integrated Parfocal Zoom Lens, f = 15–31 mm (2x) |
| Min. sensitivity | F 1.4/1.17 Lux |
| Grip mechanism | standard eyepiece adaptor |
| Cable | non-detachable |
| Cable length | 300 cm |

TH 104

TH 104 **IMAGE1 S H3-ZA Three-Chip FULL HD Camera Head,** 50/60 Hz, IMAGE1 S compatible, **autoclavable,** progressive scan, soakable, gas- and plasma-sterilizable, with integrated Parfocal Zoom Lens, focal length f = 15–31 mm (2x), 2 freely programmable camera head buttons, for use with IMAGE1 S and IMAGE1 HUB™ HD/HD

**Specifications:**

| IMAGE1 FULL HD Camera Heads | IMAGE1 S H3-ZA |
|---|---|
| Product no. | TH 104 |
| Image sensor | 3x ⅓" CCD chip |
| Dimensions w x h x d | 39 x 49 x 100 mm |
| Weight | 299 g |
| Optical interface | integrated Parfocal Zoom Lens, f = 15–31 mm (2x) |
| Min. sensitivity | F 1.4/1.17 Lux |
| Grip mechanism | standard eyepiece adaptor |
| Cable | non-detachable |
| Cable length | 300 cm |

## Monitors


9619 NB

9619 NB

**19" HD Monitor,**
color systems **PAL/NTSC,** max. screen resolution 1280 x 1024, image format 4:3, power supply 100–240 VAC, 50/60 Hz, wall-mounted with VESA 100 adaption, including:
**External 24 VDC Power Supply**
**Mains Cord**


9826 NB

9826 NB

**26" FULL HD Monitor,**
wall-mounted with VESA 100 adaption, color systems **PAL/NTSC,**
max. screen resolution 1920 x 1080, image fomat 16:9,
power supply 100–240 VAC, 50/60 Hz
including:
**External 24 VDC Power Supply**
**Mains Cord**

## Monitors

| KARL STORZ HD and FULL HD Monitors | 19" | 26" |
|---|---|---|
| **Wall-mounted with VESA 100 adaption** | 9619 NB | 9826 NB |
| **Inputs:** | | |
| DVI-D | ● | ● |
| Fibre Optic | | |
| 3G-SDI | | ● |
| RGBS (VGA) | ● | ● |
| S-Video | ● | ● |
| Composite/FBAS | ● | ● |
| **Outputs:** | | |
| DVI-D | ● | ● |
| S-Video | ● | |
| Composite/FBAS | ● | ● |
| RGBS (VGA) | ● | |
| 3G-SDI | | ● |
| **Signal Format Display:** | | |
| 4:3 | ● | ● |
| 5:4 | ● | ● |
| 16:9 | ● | ● |
| Picture-in-Picture | ● | ● |
| PAL/NTSC compatible | ● | ● |

**Optional accessories:**

9826 SF **Pedestal,** for monitor 9826 NB
9626 SF **Pedestal,** for monitor 9619 NB

**Specifications:**

| KARL STORZ HD and FULL HD Monitors | 19" | 26" |
|---|---|---|
| **Desktop with pedestal** | optional | optional |
| Product no. | 9619 NB | 9826 NB |
| Brightness | 200 cd/m² (typ) | 500 cd/m² (typ) |
| Max. viewing angle | 178° vertical | 178° vertical |
| Pixel distance | 0.29 mm | 0.3 mm |
| Reaction time | 5 ms | 8 ms |
| Contrast ratio | 700:1 | 1400:1 |
| Mount | 100 mm VESA | 100 mm VESA |
| Weight | 7.6 kg | 7.7 kg |
| Rated power | 28 W | 72 W |
| Operating conditions | 0–40°C | 5–35°C |
| Storage | -20–60°C | -20–60°C |
| Rel. humidity | max. 85% | max. 85% |
| Dimensions w x h x d | 469.5 x 416 x 75.5 mm | 643 x 396 x 87 mm |
| Power supply | 100–240 VAC | 100–240 VAC |
| Certified to | EN 60601-1, protection class IPX0 | EN 60601-1, UL 60601-1, MDD93/42/EEC, protection class IPX2 |

## Cold Light Fountain Power LED 175 SCB


| | |
|---|---|
| **20**1614 01-1 | **Cold Light Fountain Power LED 175 SCB,** with integrated SCB, high-performance LED and one KARL STORZ light outlet, power supply 110–240 VAC, 50/60 Hz<br>including:<br>**Cold Light Fountain Power LED**<br>**Mains Cord**<br>**SCB Connecting Cable,** length 100 cm |
| **20**1320 26 | **Xenon-Spare-Lamp,** 175 watt, 15 volt |

## Fiber Optic Light Cables

**for Cold Light Fountains**

| | |
|---|---|
| 495 NL | **Fiber Optic Light Cable,** straight connector, diameter 3.5 mm, length 180 cm |
| 495 NA | **Same,** diameter 3.5 mm, length 230 cm |

## Equipment Cart

UG 220

UG 220

**Equipment Cart**
wide, high, rides on 4 antistatic dual wheels
equipped with locking brakes 3 shelves,
mains switch on top cover,
central beam with integrated electrical subdistributors
with 12 sockets, holder for power supplies,
potential earth connectors and cable winding
on the outside,

*Dimensions:*
*Equipment cart: 830 x 1474 x 730 mm (w x h x d),*
*shelf: 630 x 510 mm (w x d),*
*caster diameter: 150 mm*

inluding:

**Base module equipment cart,** wide
**Cover equipment,** equipment cart wide
**Beam package equipment,** equipment cart high
3x **Shelf,** wide
**Drawer unit with lock,** wide
2x **Equipment rail,** long
**Camera holder**

UG 540

UG 540

**Monitor Swifel Arm,**
height and side adjustable,
can be turned to the left or the right side,
swivel range 180°, overhang 780 mm,
overhang from centre 1170 mm,
load capacity max. 15 kg,
with monitor fixation VESA 5/100,
for usage with equipment carts UG xxx

## Recommended Accessories for Equipment Cart

UG 310

UG 310 **Isolation Transformer,**
200 V–240 V; 2000 VA with 3 special mains socket,
expulsion fuses, 3 grounding plugs,
dimensions: 330 x 90 x 495 mm (w x h x d),
for usage with equipment carts UG xxx

UG 410

UG 410 **Earth Leakage Monitor,**
200 V–240 V, for mounting at equipment cart,
control panel dimensions: 44 x 80 x 29 mm (w x h x d),
for usage with isolation transformer UG 310

UG 510

UG 510 **Monitor Holding Arm,**
height adjustable, inclinable,
mountable on left or right,
turning radius approx. 320°, overhang 530 mm,
load capacity max. 15 kg,
monitor fixation VESA 75/100,
for usage with equipment carts UG xxx

WITH COMPLIMENTS OF
KARL STORZ—ENDOSKOPE